

## BRIEF COMMUNICATION

# Treatment of acquired transthyretin amyloidosis in domino liver transplantation

Konstantinos I. Tsamis<sup>1,2</sup>  | Dimitrios Mytilinaios<sup>3</sup> | Michael Heneghan<sup>4</sup> |  
 Julian D. Gillmore<sup>5</sup> | Janet A. Gilbertson<sup>5</sup> | Sotirios Giannopoulos<sup>2,6</sup> |  
 Ioannis Sarmas<sup>2</sup> | Spyridon Konitsiotis<sup>2</sup>

<sup>1</sup>Faculty of Medicine, Department of Physiology, School of Health Sciences, University of Ioannina, Ioannina, Greece

<sup>2</sup>Department of Neurology, University Hospital of Ioannina, University of Ioannina, Ioannina, Greece

<sup>3</sup>Kenhub GmbH, Leipzig, Germany

<sup>4</sup>Hepatology Department, Institute of Liver Studies, King's College Hospital, London, UK

<sup>5</sup>National Amyloidosis Centre, Division of Medicine, University College London, Royal Free Campus, London, UK

<sup>6</sup>Second Department of Neurology, National & Kapodistrian University of Athens, School of Medicine, "Attikon" University Hospital, Athens, Greece

## Correspondence

Konstantinos I. Tsamis, Faculty of Medicine, Department of Physiology, School of Health Sciences, University of Ioannina, Ioannina 45110, Greece.

Email: [ktsamis@uoi.gr](mailto:ktsamis@uoi.gr)

## Abstract

**Background:** Domino liver transplantation (DLT) has been commonly used during the last two decades to partly meet the high need for liver transplants. However, the recipients of grafts from patients with noncirrhotic inherited metabolic disorders may ultimately develop metabolic syndrome, and management is usually intricate, being complicated by the underlying initial disorder, other comorbidities, and post-transplantation conditions.

**Case:** We report here the management and the outcome in a patient with acquired transthyretin amyloidosis after DLT and significant comorbidities. Final treatment with a transthyretin gene silencing agent, patisiran, was well tolerated and resulted in remission of the aggravating neurological deficits in a follow-up period of 2 years.

**Conclusions:** The case presented here supports the concept that patisiran can target the hepatocytes producing the mutated transthyretin in acquired transthyretin amyloidosis, as efficiently as in hereditary transthyretin amyloidosis (hATTR), and can be used to treat patients with transthyretin amyloidosis after DLT.

## KEYWORDS

amyloidosis, liver transplant, patisiran, RNA interference, transthyretin

## 1 | INTRODUCTION

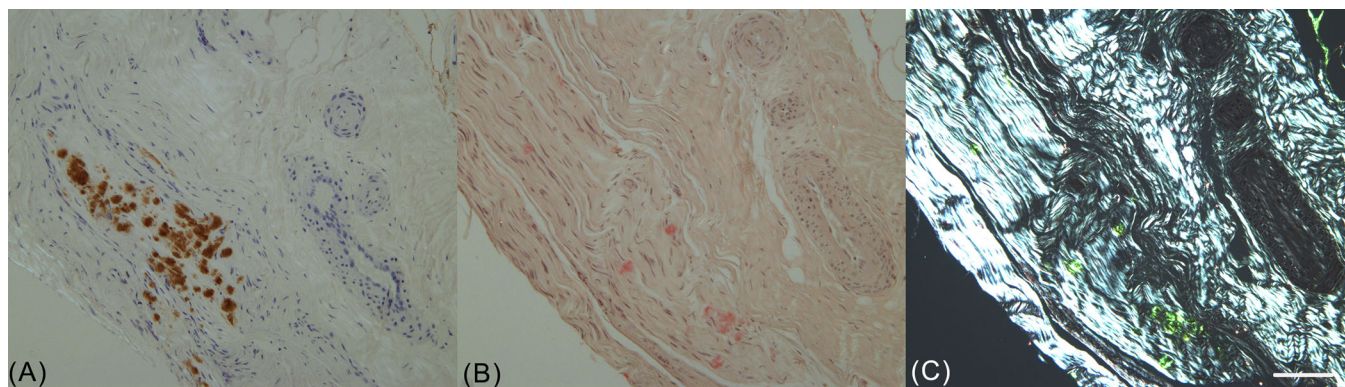
High international need for liver transplantation along with the scarcity of donor organs has led to the use of liver grafts from marginal donors, after refinement of handling and surgical techniques.<sup>1</sup> Further expansion of the donor pool has also been achieved during the last decades through domino liver transplantation (DLT), using grafts explanted from patients with metabolic diseases and transplanted to patients with end-stage liver diseases.<sup>2,3</sup> In DLT, patients with selected non-cirrhotic inherited metabolic disorders receiving an orthotopic liver transplantation serve as intermediate donors, providing liver grafts or hepatocytes for the treatment of patients with liver cirrhosis or

hepatocellular carcinoma. However, the ultimate recipients usually develop metabolic syndrome within various periods of time and of varying severity.<sup>4</sup>

Among other metabolic disorders involved in DLT, hereditary transthyretin amyloidosis (hATTR) is the most common indication.<sup>5</sup> hATTR is a multisystem disorder caused by mutations in the transthyretin (TTR) gene. The inheritance of this condition is autosomal-dominant, with variable penetrance, and it presents as an adult-onset disorder.<sup>6</sup> It affects different organs with the deposition of amyloid fibrils, leading primarily to peripheral nervous system impairment and cardiac involvement, formerly known as familial amyloidotic polyneuropathy (FAP) and familial amyloidotic

This is an open access article under the terms of the [Creative Commons Attribution-NonCommercial](https://creativecommons.org/licenses/by-nc/4.0/) License, which permits use, distribution and reproduction in any medium, provided the original work is properly cited and is not used for commercial purposes.

© 2022 The Authors. *Clinical Transplantation* published by John Wiley & Sons Ltd.



**FIGURE 1** Patient's nerve biopsy. Immunohistochemistry for TTR (A), Congo red staining (B), and Congo red under polarized light (C). Scale bar: 100  $\mu\text{m}$

cardiomyopathy (FAC).<sup>7</sup> Therapeutic approaches for hATTR include (a) liver transplantation, reducing variant TTR production since most such production takes place in the liver, (b) tetramer stabilizing agents, preventing TTR fibril formation, and (c) TTR gene silencing agents, ending the production of the mutant and wild-type forms of TTR.<sup>8–10</sup>

The initial expectation for DLT recipients of liver grafts from patients with hATTR was that the recurrent syndrome would have minimal effect, since the production and hoarding of amyloid fibrils is a time-consuming process.<sup>11</sup> However, in 2005, the first case of acquired transthyretin amyloidosis (aqATTR) was reported in a patient 8 years after DLT.<sup>12</sup> Subsequent studies with long-term follow-up confirmed this finding, revealing that several patients developed *de novo* amyloidosis, comprising a combined form in which wild-type ATTR amyloid was deposited on the existing template of variant ATTR amyloid somewhat earlier than expected (between 3 and 9 years post-DLT) and that the aging of the recipients accelerated the aqATTR.<sup>13,14</sup> More recent publications have further confirmed these findings, describing an incidence of post-DLT aqATTR between 7.1% and 16.4% for biopsy-confirmed cases.<sup>15,16</sup> Thus, an increasing need for the management of aqATTR has emerged, especially for elderly patients and patients with multiple comorbidities, with the aim of reducing disability and mortality. Currently, however, there is a paucity of data on the treatment outcome of these patients.<sup>17</sup>

## 2 | CASE PRESENTATION

We report an 80-year-old male patient suffering from aqATTR that occurred after DLT was performed for hepatocellular carcinoma. His previous medical history included hepatitis B, diagnosed in 1988 and treated with interferon in 1990, and coronary heart disease, diagnosed in 2000. In 2003, he was diagnosed with hepatocellular carcinoma (T2/N0/M0 stage in TNM classification), and in 2007, he underwent a liver transplant at Kings College Hospital from a compatible donor, who, in turn, underwent a transplant due to familial amyloidosis, with a TTR Met 30 mutation.

The patient was followed up in the University Hospital of Ioannina, Greece, with no recurrence in imaging studies and stable liver function in laboratory workup under treatment with tenofovir. After about 8 years, he developed bradyarrhythmia and, 2 years later, symptoms from the peripheral nervous system, mainly distal limb paresthesia, tingling, and mild weakness. From the gastrointestinal tract, he experienced periods of diarrhea followed by constipation and concomitant abdominal pain. From the cardiovascular system, there was pre-existing coronary heart disease, but during 2015, his bradyarrhythmia worsened, leading to the placement of a pacemaker, and he also developed an abdominal aortic aneurysm. The initial clinical and laboratory examination revealed polyneuropathy with absent tendon reflexes and severely affected sensory conduction in nerve conduction studies. The history of DLT from a donor with hATTR led the diagnostic approach to nerve biopsy, which confirmed the diagnosis of amyloid polyneuropathy (Figure 1). On the other hand, aqATTR cardiomyopathy was excluded, based on the history of coronary heart disease prior to DLT and the absence of typical echocardiographic findings.<sup>18,19</sup> The arrhythmia was associated with the heart disease, along with possible autonomic nervous system involvement, while the aneurysm was attributed to the liver transplantation.<sup>20</sup> Renal and ocular involvement was not observed.

At the time of diagnosis, clinical evaluation of the patient classified him at FAP stage 1 and polyneuropathy disability (PND) score 2.<sup>21</sup> He immediately started treatment with tafamidis (20 mg orally once daily) in November 2018 but then underwent a slow and steady aggravation of his neurological deficits, which, in spring 2020, reached a critical point (FAP stage 2 and PND score 3B). At this point, the progression of the aqATTR was about to lead the patient to the final stage of amyloid polyneuropathy, confining him to a wheelchair. Accelerated disease progression was compatible with the age of the patient, as described in previous studies.<sup>14</sup> Thus, it was decided that the patient should have a gene silencing treatment to stop the progression of aqATTR as a rescuing therapy. Patisiran treatment was started in summer 2020, at a dose of 300  $\mu\text{g}$  per kg body weight administered intravenously once every 3 weeks, with intravenous premedication of corticosteroid and H1/H2 blockers as well as 2500 IU vitamin A supplementation per day. During

the first 3 months of the treatment, the patient's condition stabilized in FAP stage 2 and PND score 3B. Over the next months, the patient experienced a slow and steady improvement, bringing him back to FAP stage 1 and PND score 2.

Two years after the initiation of the treatment with patisiran, the patient remained in a stable neurologic condition. It is also important to note that the patient was affected by multiple comorbidities, diagnosed before initiation of patisiran treatment, such as coronary heart disease, abdominal aortic aneurism, and chronic lymphocytic leukemia (low risk, lymphocytosis without other symptoms), and was receiving complex medication with antiviral agents for hepatitis. These disorders, the laboratory tests, and the medication were not significantly affected by the addition of patisiran treatment.

### 3 | DISCUSSION AND CONCLUSION

To the best of our knowledge, this is the first case reported in the literature to receive a gene silencing agent for the treatment of aqATTR due to DLT. After 2 years' follow-up, we can assume that patisiran treatment was well tolerated by the patient and very efficient, despite his age and the comorbidities, since it managed to reverse the aggravating neurological deficits.

Patisiran is one of the very first gene silencing agents to have entered clinical practice. Its development was based on the revolutionary observation of the robust effect that the double-stranded interfering RNA can exert on gene expression, published in 1998.<sup>22</sup> Further research on the so-called small interfering RNA (siRNA) led to the development of patisiran and the clinical validation of its safety and efficacy.<sup>23–24</sup> The delivery system of patisiran, based on lipid nanoparticles, was designed to target hepatocytes in the liver, where the drug molecules are uptaken, releasing siRNA in the cytoplasm. This reduces the production of TTR protein, as siRNA breaks down TTR mRNA.<sup>8</sup> Thus, it is obvious from the mechanism of action of this nucleic acid treatment that it could reach the target hepatocytes producing the mutated TTR, both in hATTR and aqATTR, and the case presented here supports this concept.

To date, numerous patients with hATTR worldwide have been treated with patisiran, and a wealth of information shows minimal side effects and high effectiveness in the improvement of both neurological and cardiovascular symptoms.<sup>25–28</sup> TTR silencing agents are a novel, life-changing treatment strategy for ATTR and might even make liver transplantation, including DLT, irrelevant for these patients in the near future.<sup>29,30</sup> However, there is a large number of patients around the world that have already received liver transplantation for hATTR. Disease progression may continue after transplantation, and patisiran can serve as an effective treatment for such patients, according to recent data.<sup>31</sup> Moreover, a significant number of patients has already received DLT.<sup>15</sup> These patients, upon development of aqATTR polyneuropathy, could be candidates for TTR silencing treatment, based on the case presented here and the paucity of existing data on the treatment outcome for post-DLT aqATTR.<sup>17</sup>

### AUTHOR CONTRIBUTIONS

Konstantinos I. Tsamis, Sotirios Giannopoulos, Ioannis Sarmas, and Spyridon Konitsiotis contributed to the conception and design of the paper. Konstantinos I. Tsamis, Michael Heneghan, Julian D. Gillmore, Ioannis Sarmas, Spyridon Konitsiotis, and Janet A. Gilbertson contributed to the acquisition and analysis of data. Konstantinos I. Tsamis, Dimitrios Mytilinaios, and Janet A. Gilbertson contributed to drafting a significant portion of the manuscript and figures.

### CONFLICTS OF INTEREST

K. I. T. has received honoraria from and/or participated in research sponsored by Allergan, Abbvie, Genesis, and Sanofi. M. H. has received honoraria from Roche, Novartis, Moderna, and Eledon Pharmaceuticals. J. D. G. has provided expert advisory services to Alnylam, Eidos, Intellia, Ionis, and Pfizer. S. G. has received honoraria from CSL Boehringer, Boehringer Ingelheim, and Bayer Hellas. S. K. has received honoraria from and/or participated in clinical trials sponsored by Genesis, Novartis, Merck, Teva, Abbvie, UCB, Medronic, Sanofi, and Roche.

### DATA AVAILABILITY STATEMENT

The data that support the findings of this study are available on request from the corresponding author. The data are not publicly available due to privacy or ethical restrictions.

### ORCID

Konstantinos I. Tsamis  <https://orcid.org/0000-0002-7032-1630>

### REFERENCES

- Bodzin AS, Baker TB. Liver transplantation today: where we are now and where we are going. *Liver Transplant*. 2018;24(10):1470–1475.
- Celik N, Squires JE, Soltys K, et al. Domino liver transplantation for select metabolic disorders: expanding the living donor pool. *JIMD Rep*. 2019;48(1):83–89.
- Zhou G-P, Sun L-Y, Zhu Z-J. The concept of “domino” in liver and hepatocyte transplantation. *Ther Adv Gastroenterol*. 2020;13:1756284820968755.
- Popescu I, Dima SO. Domino liver transplantation: how far can we push the paradigm? *Liver Transplant*. 2012;18(1):22–28.
- Santopaolo F, Lenci I, Bosa A, Angelico M, Milana M, Baiocchi L. Domino liver transplantation: where are we now? *Rev Recent Clin Trials*. 2019;14(3):183–188.
- Luigetti M, Romano A, di Paolantonio A, Bisogni G, Sabatelli M. Diagnosis and treatment of hereditary transthyretin amyloidosis (hATTR) polyneuropathy: current perspectives on improving patient care. *Ther Clin Risk Manag*. 2020;16:109–123.
- Koike H, Okumura T, Murohara T, Katsuno M. Multidisciplinary approaches for transthyretin amyloidosis. *Cardiol Ther*. 2021;10(2):289–311.
- Luigetti M, Servidei S. Patisiran in hereditary transthyretin-mediated amyloidosis. *Lancet Neurol*. 2021;20(1):21–23.
- Mahfouz M, Maruyama R, Yokota T. Inotersen for the treatment of hereditary transthyretin amyloidosis. *Methods Mol Biol*. 2020;2176:87–98.
- Cristóbal Gutiérrez H, Pelayo-Negro AL, Gómez D, Martín Vega MÁ, Valero Domínguez M. Overview of treatments used in transthyretin-related hereditary amyloidosis: a systematic review. *Eur J Hosp Pharmacy*. 2020;27(4):194–201.

11. Dovidchenko NV, Leonovo EI, Galzitskaya OV. Mechanisms of amyloid fibril formation. *Biochemistry (Moscow)*. 2014;79(13):1515-1527.
12. Stangou AJ, Heaton ND, Hawkins PN. Transmission of systemic transthyretin amyloidosis by means of domino liver transplantation. *N Engl J Med*. 2005;352(22):2356.
13. Vollmar J, Schmid JC, Hoppe-Lotichius M, et al. Progression of transthyretin (TTR) amyloidosis in donors and recipients after domino liver transplantation—a prospective single-center cohort study. *Transpl Int*. 2018;31(11):1207-1215.
14. Misumi Y, Narita Y, Oshima T, et al. Recipient aging accelerates acquired transthyretin amyloidosis after domino liver transplantation. *Liver Transpl*. 2016;22(5):656-664.
15. Barros I, Mateus E, Coelho JS, et al. Domino liver transplantation: current status. *Surgery, Gastroenterol Oncol*. 2021;26(1):14-18.
16. Marques HP, Barros I, Li J, Murad SD, di Benedetto F. Current update in domino liver transplantation. *Int J Surg*. 2020;82S:163-168.
17. Misumi Y, Ueda M, Masuda T, et al. Characteristics of acquired transthyretin amyloidosis: a case series and review of the literature. *Neurology*. 2019;93(17):e1587-e1596.
18. Pagourelas ED, Mirea O, Duchenne J, et al. Echo parameters for differential diagnosis in cardiac amyloidosis: a head-to-head comparison of deformation and nondeformation parameters. *Circ Cardiovasc Imaging*. 2017;10(3):e005588.
19. Garcia-Pavia P, Rapezzi C, Adler Y, et al. Diagnosis and treatment of cardiac amyloidosis. A position statement of the European Society of Cardiology Working Group on Myocardial and Pericardial Diseases. *Eur J Heart Fail*. 2021;23(4):512-526.
20. Cron DC, Coleman DM, Sheetz KH, Englesbe MJ, Waits SA. Aneurysms in abdominal organ transplant recipients. *J Vasc Surg*. 2014;59(3):594-598.
21. Adams D. Recent advances in the treatment of familial amyloid polyneuropathy. *Ther Adv Neurol Disord*. 2013;6(2):129-139.
22. Fire A, Xu S, Montgomery MK, Kostas SA, Driver SE, Mello CC. Potent and specific genetic interference by double-stranded RNA in *Caenorhabditis elegans*. *Nature*. 1998;391(6669):806-811.
23. Adams D, Gonzalez-Duarte A, O'Riordan WD, et al. Patisiran, an RNAi therapeutic, for hereditary transthyretin amyloidosis. *N Engl J Med*. 2018;379(1):11-21.
24. Kristen AV, Ajroud-Driss S, Conceição I, Gorevic P, Kyriakides T, Obici L. Patisiran, an RNAi therapeutic for the treatment of hereditary transthyretin-mediated amyloidosis. *Neurodegener Dis Manag*. 2019;9(1):5-23.
25. Di Stefano V, Fava A, Gentile L, et al. Italian real-life experience of patients with hereditary transthyretin amyloidosis treated with patisiran. *Pharmgenomics Pers Med*. 2022;15:499-514.
26. Kitakata H, Moriyama H, Endo J, Ikura H, Fukuda K, Sano M. Treatment of transthyretin His88Arg amyloidosis with RNA interference therapy: a case report. *J Cardiol Cases*. 2022;25(6):363-366.
27. Aimo A, Castiglione V, Rapezzi C, et al. RNA-targeting and gene editing therapies for transthyretin amyloidosis. *Nat Rev Cardiol*. 2022;19(10):655-667.
28. Kitaoka H, Izumi C, Izumiya Y, et al. JCS 2020 guideline on diagnosis and treatment of cardiac amyloidosis. *Circ J*. 2020;84(9):1610-1671.
29. Kittleson MM, Maurer MS, Ambardekar AV, et al. Cardiac amyloidosis: evolving diagnosis and management: a scientific statement from the American Heart Association Circulation. *Circulation*. 2020;142(1):e7-e22.
30. Antonopoulos AS, Panagiotopoulos I, Kouroutzoglou A, et al. Prevalence and clinical outcomes of transthyretin amyloidosis: a systematic review and meta-analysis. *Eur J Heart Fail*. Published online June 22, 2022. doi:10.1002/ejhf.2589
31. Schmidt HH, Wixner J, Planté-Bordeneuve V, et al. Patisiran treatment in patients with hereditary transthyretin-mediated amyloidosis with polyneuropathy after liver transplantation. *Am J Transplant*. 2022;22(6):1646-1657.

**How to cite this article:** Tsamis KI, Mytilinaios D, Heneghan M, et al. Treatment of acquired transthyretin amyloidosis in domino liver transplantation. *Clin Transplant*. 2023;37:e14822. <https://doi.org/10.1111/ctr.14822>